

# Case 1

**72 year-old lady**

**C.C.: Low back pain and Rt.leg pain  
for 6 months**

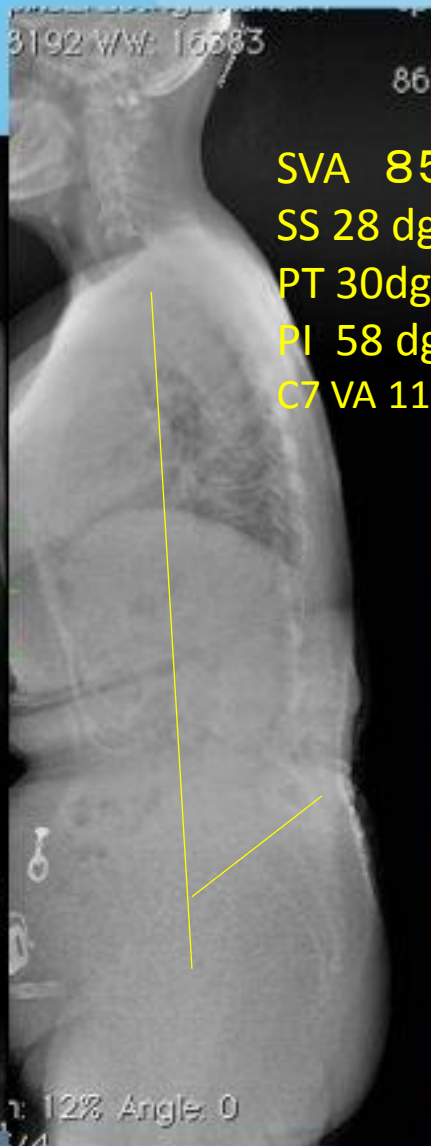
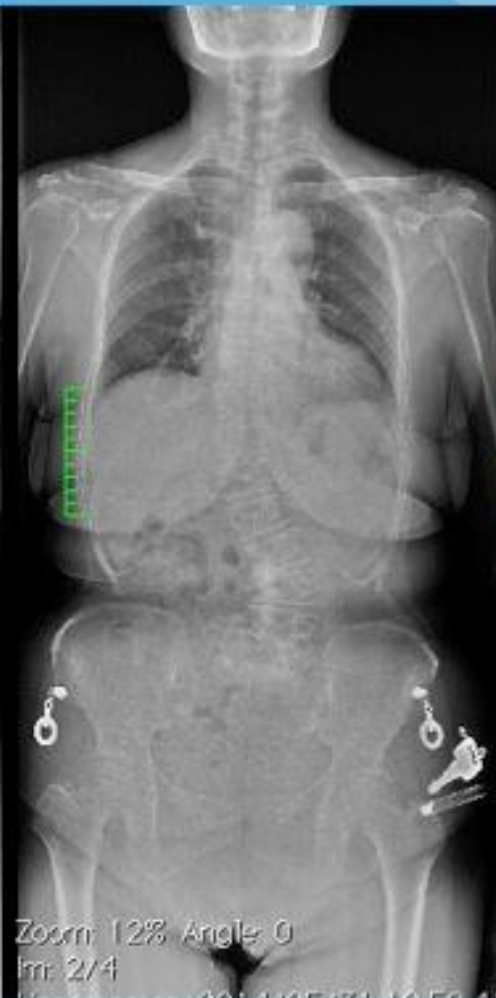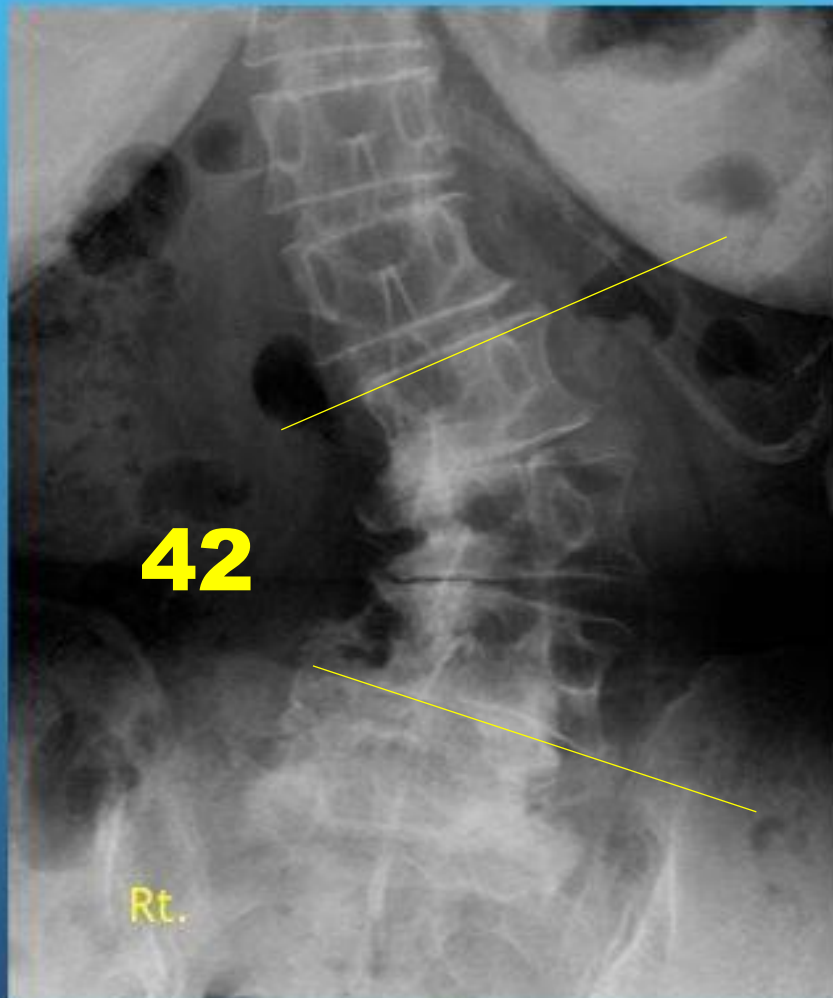
**Intermittent claudication : 50 m.**

**PHx: Asymptomatic Cerebral  
Infarction**

**PEx: MMT : Full, Sensory:normal**

**DTRs: PTR & ATR +/-**

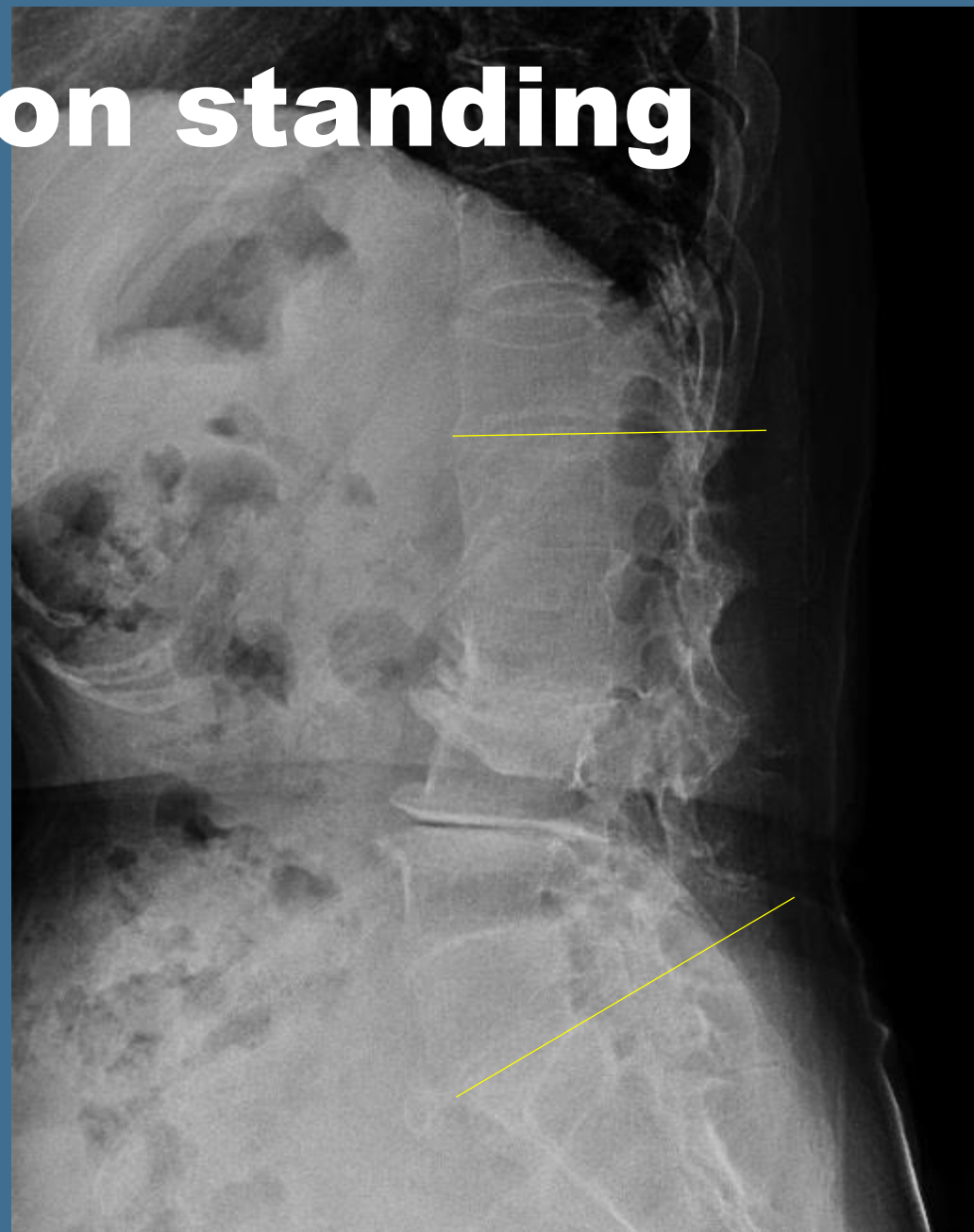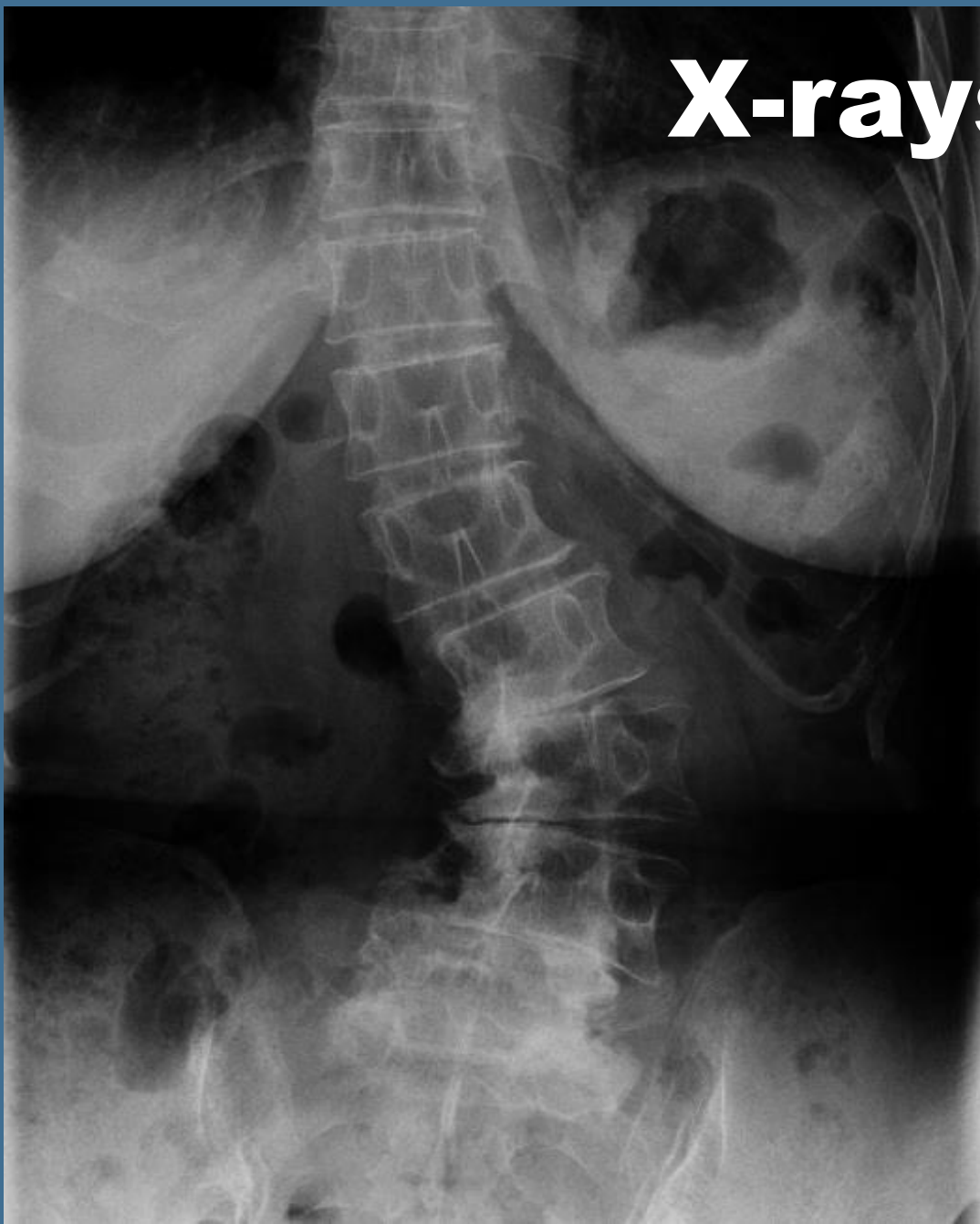# X-rays



SVA 85mm  
SS 28 dgrs  
PT 30dgrs  
PI 58 dgrs  
C7 VA 11dgrs

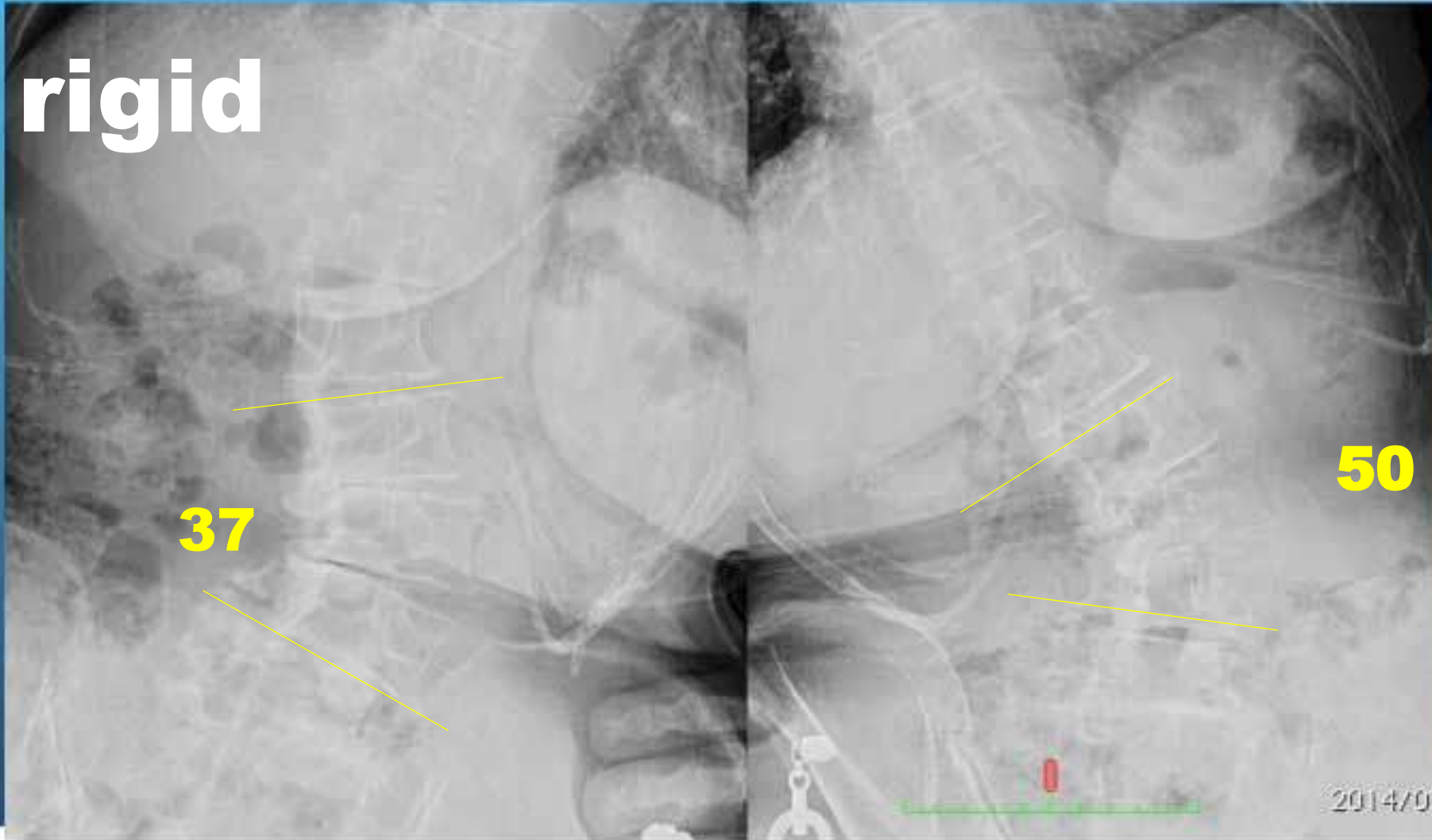SVA 85mm  
SS 28 dgrs  
PT 30dgrs  
PI 58 dgrs

# X-rays on standing



# Lateral Bending X-rays

**rigid**

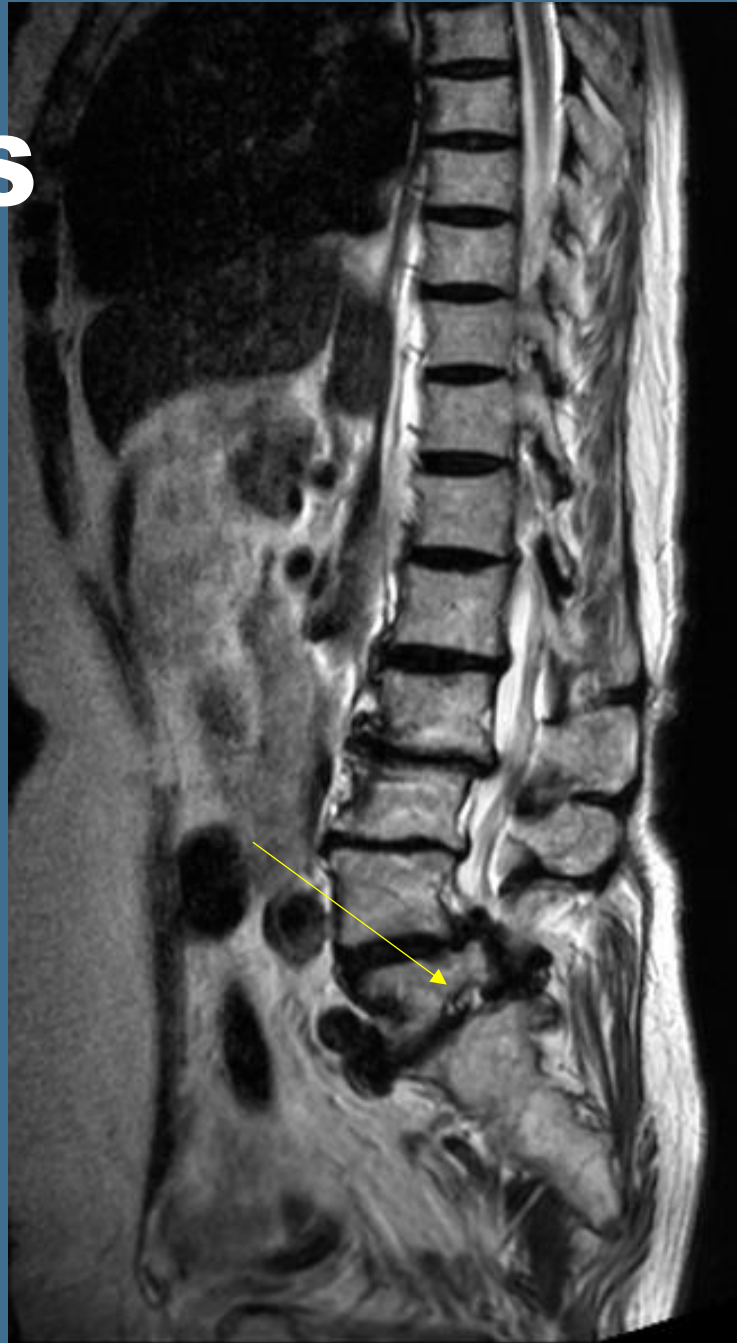
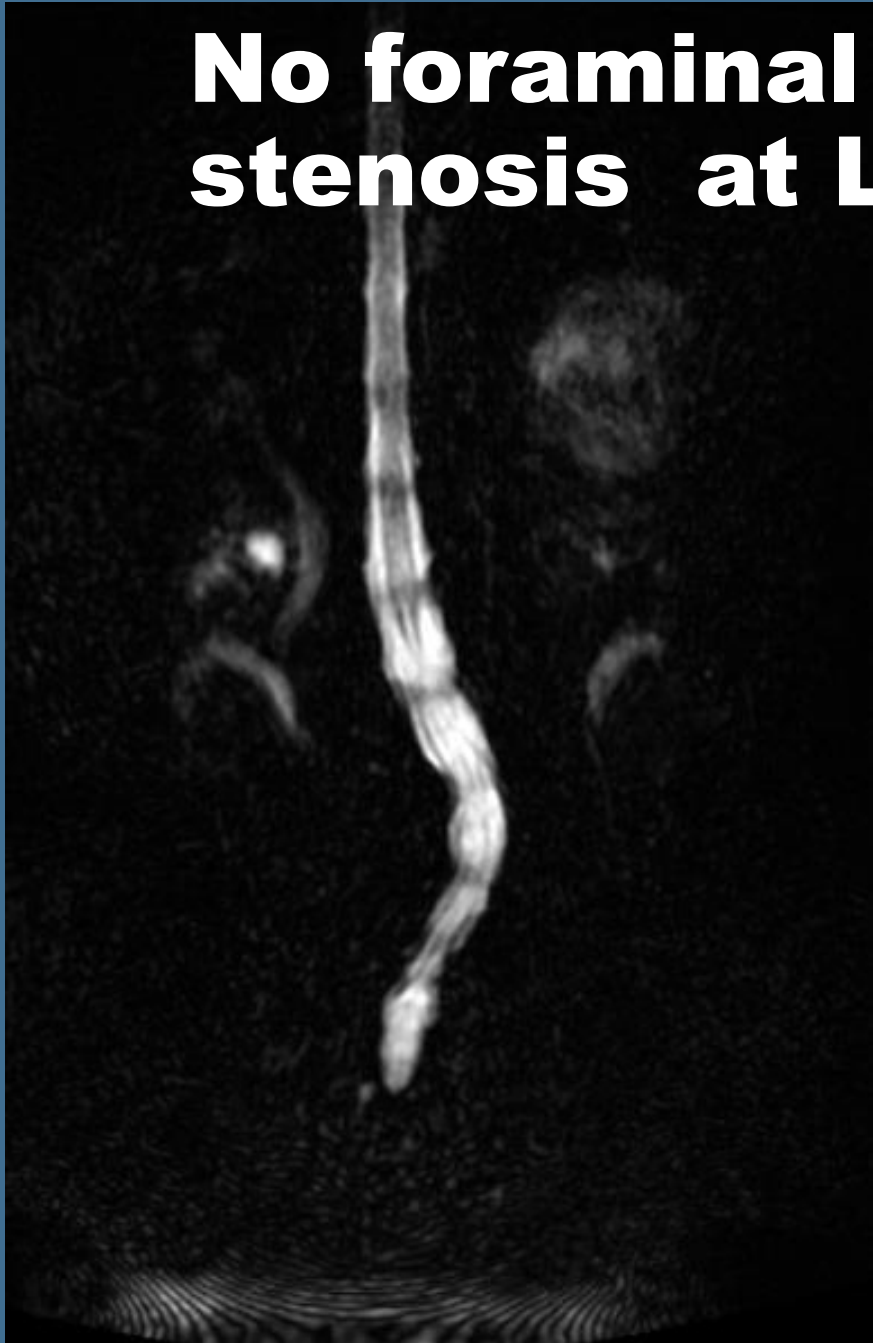
**37**

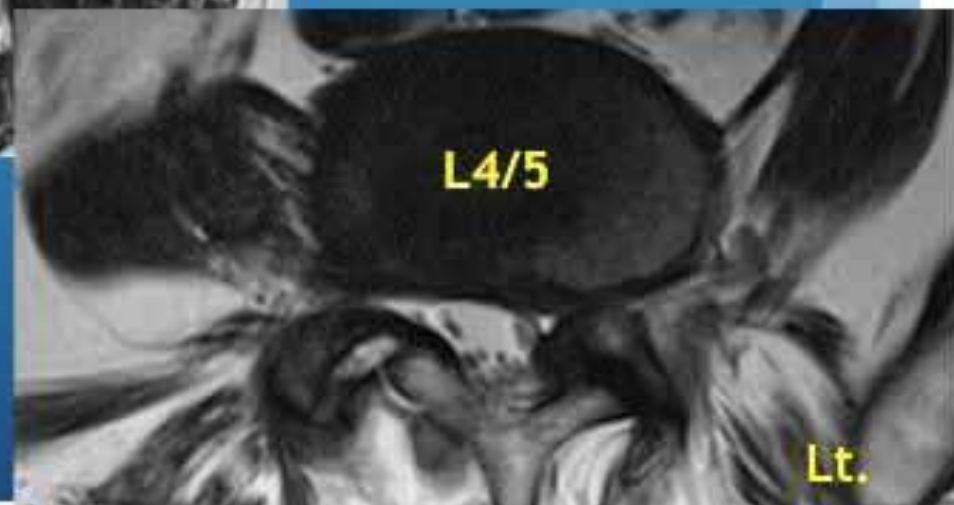
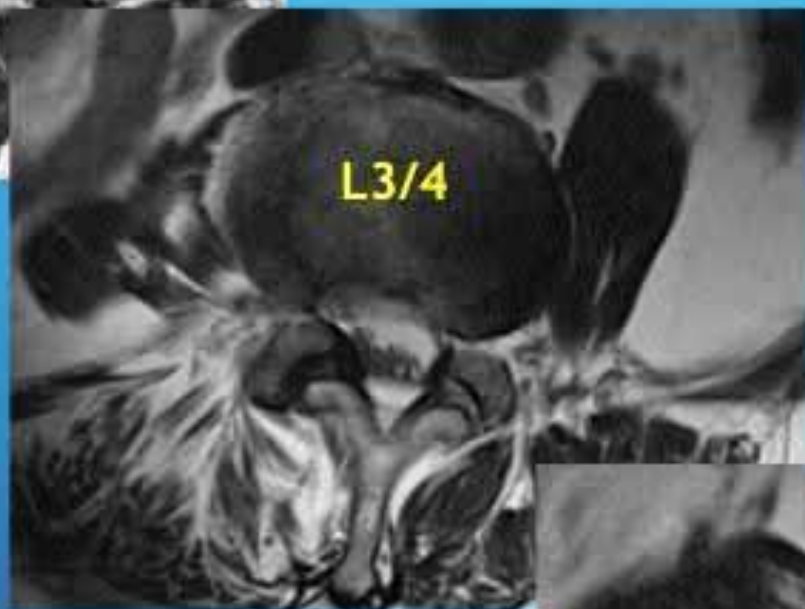
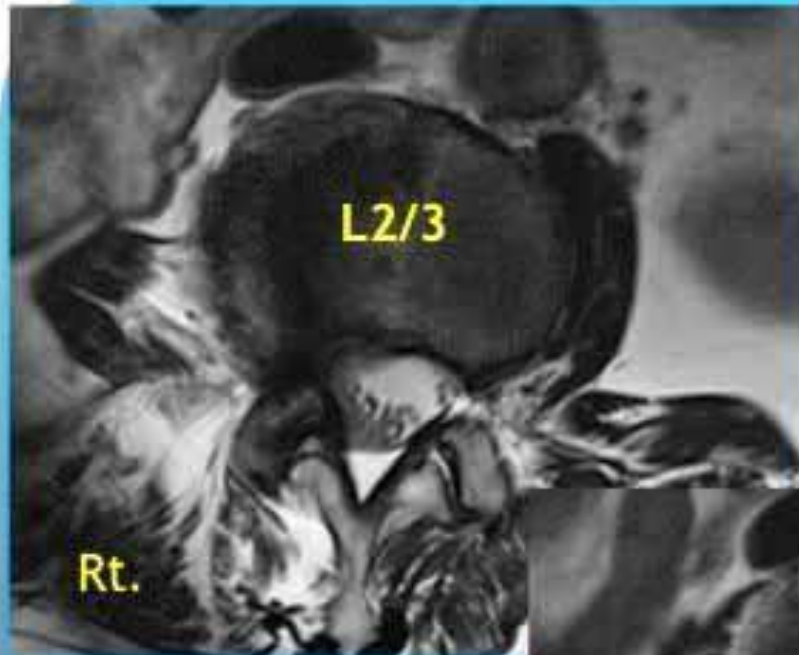
**50**

2014/05

**No foraminal  
stenosis at L5/S**



# MRI



CT

**No foraminal stenosis at L5/S**

