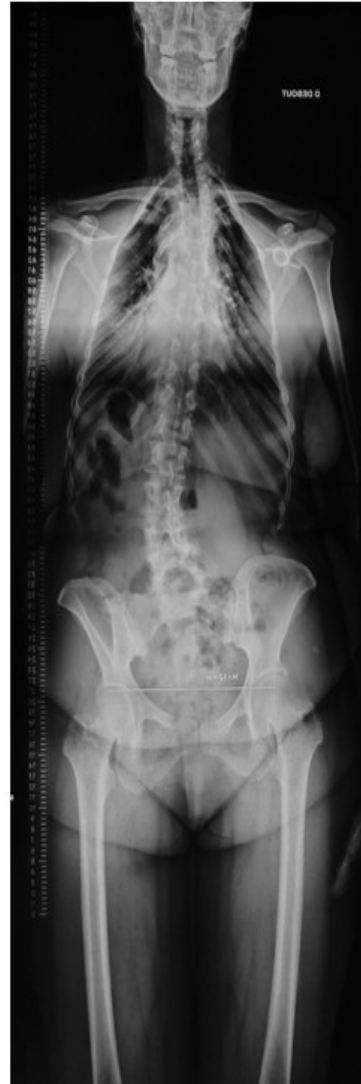
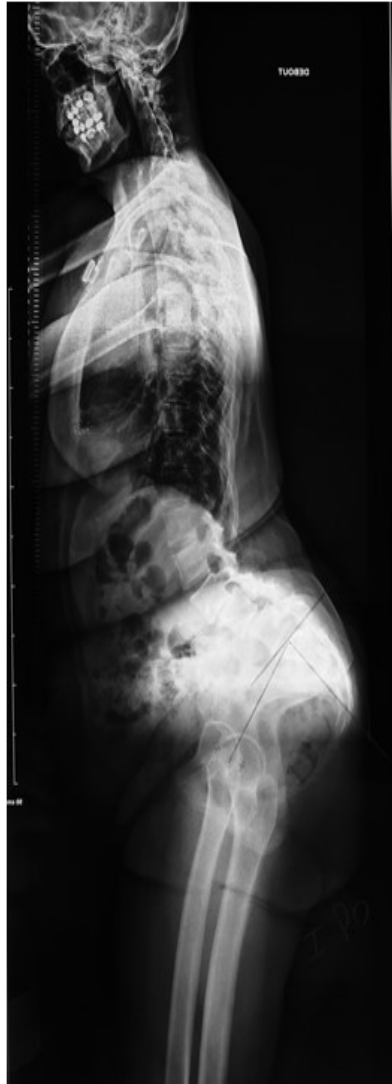
The case of Dr. Sebastien Charosky

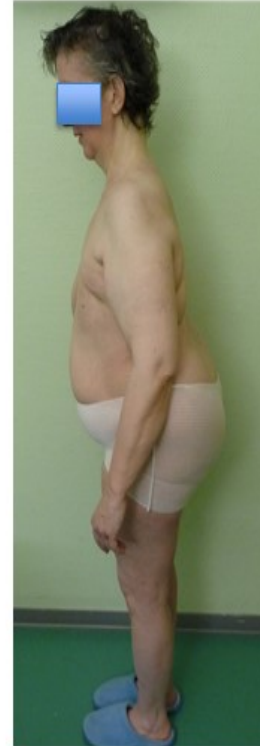
**All of images were sent
from Dr. S. Charosky
on 6 Feb.2018**

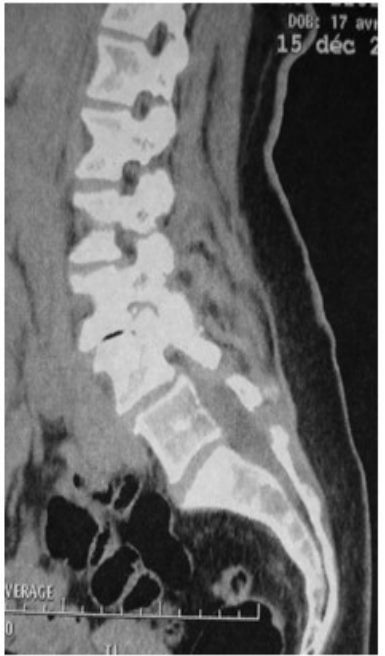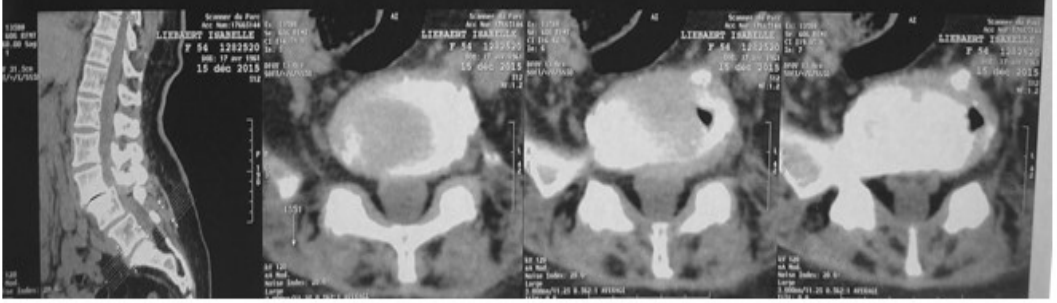
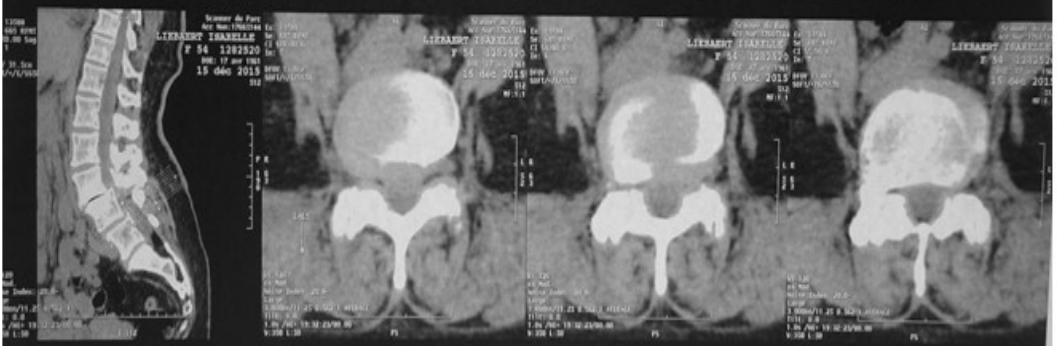
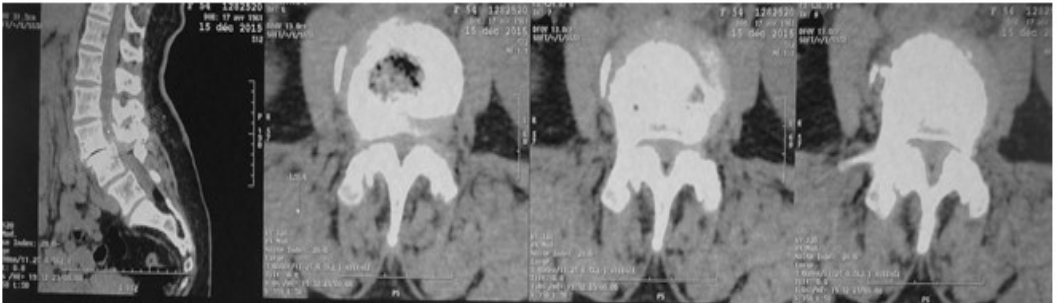
Dr.Kosei Nagata

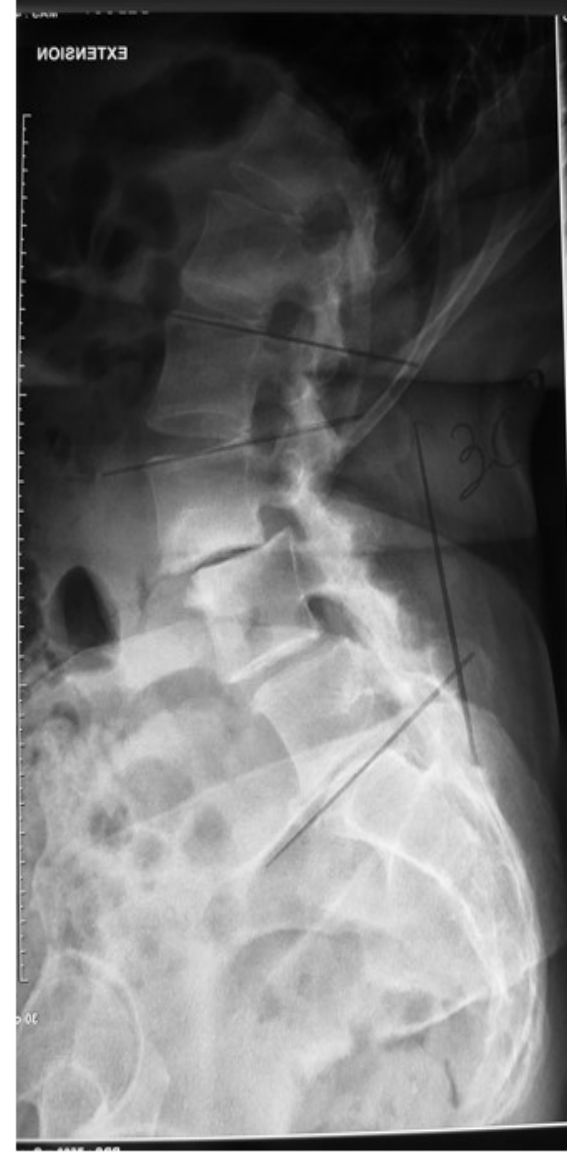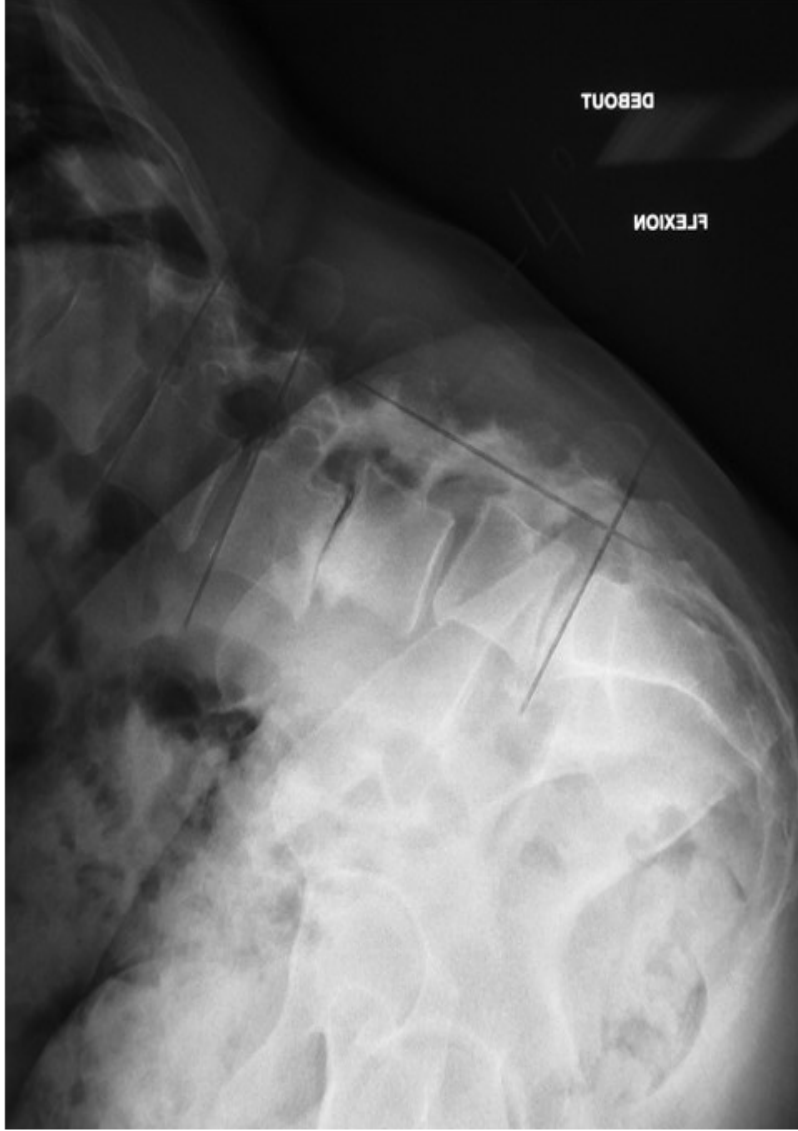
Case 1

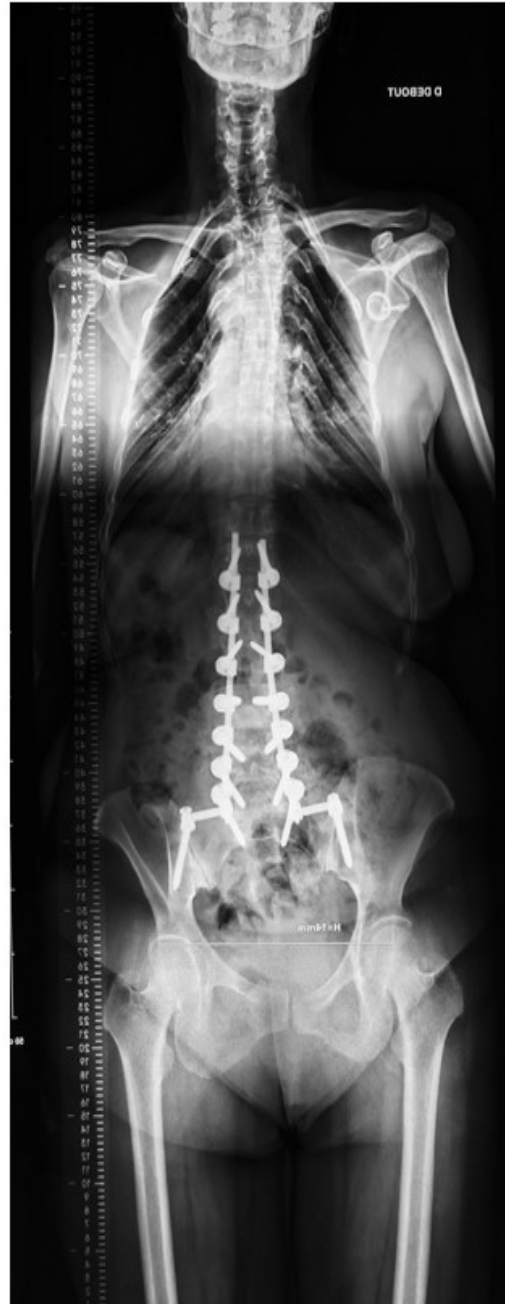
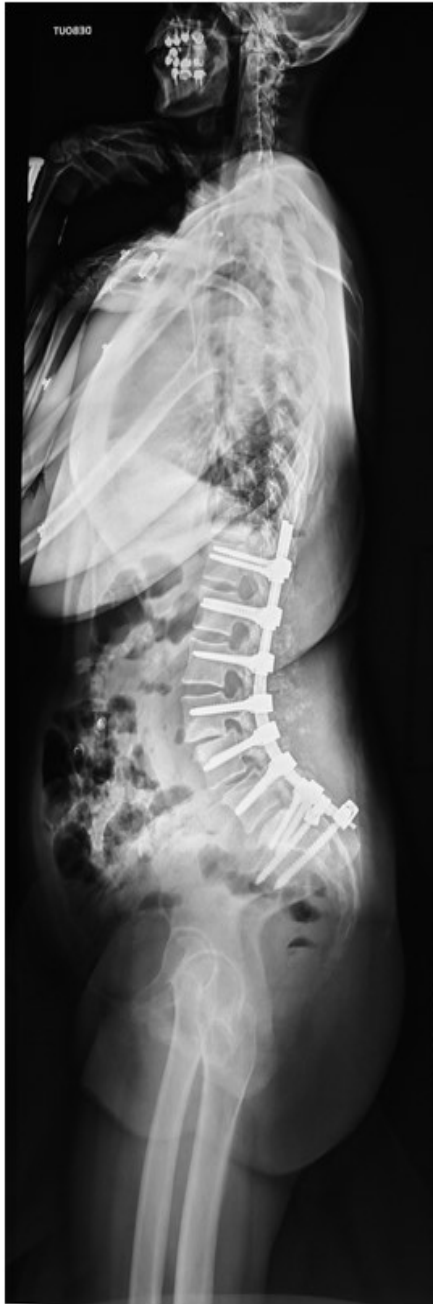
55y

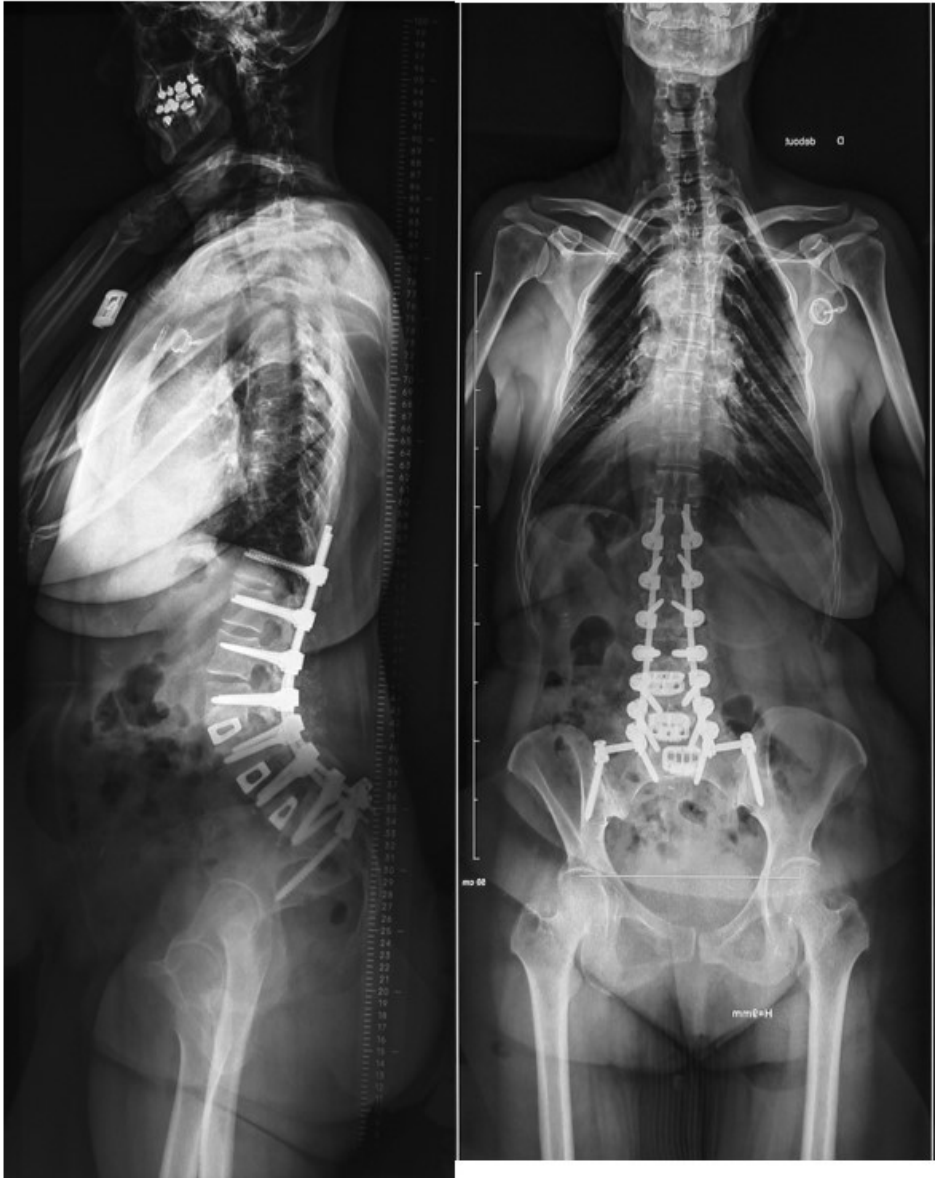



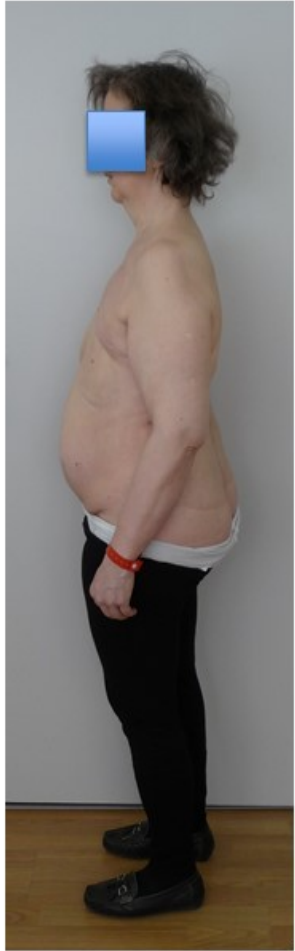



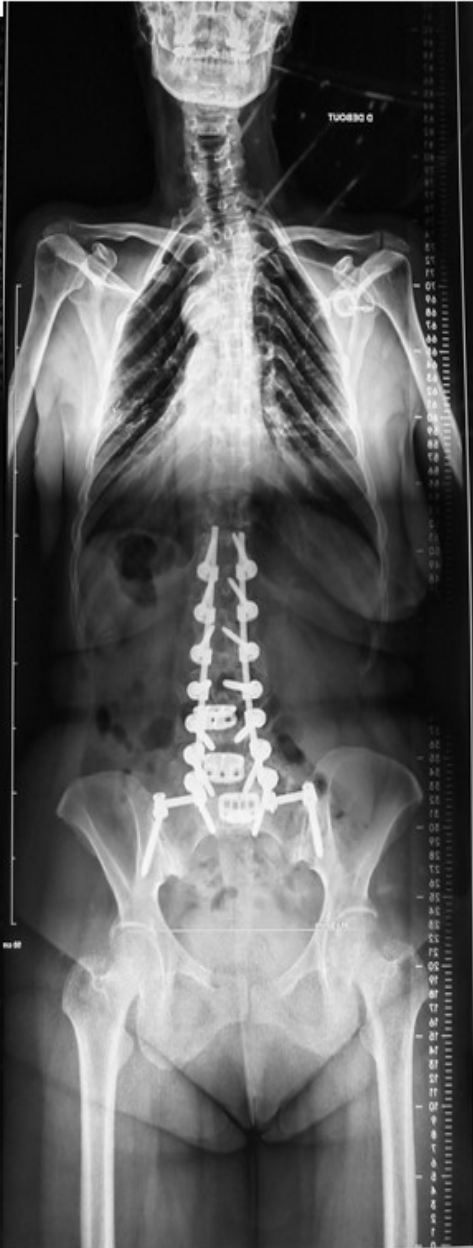
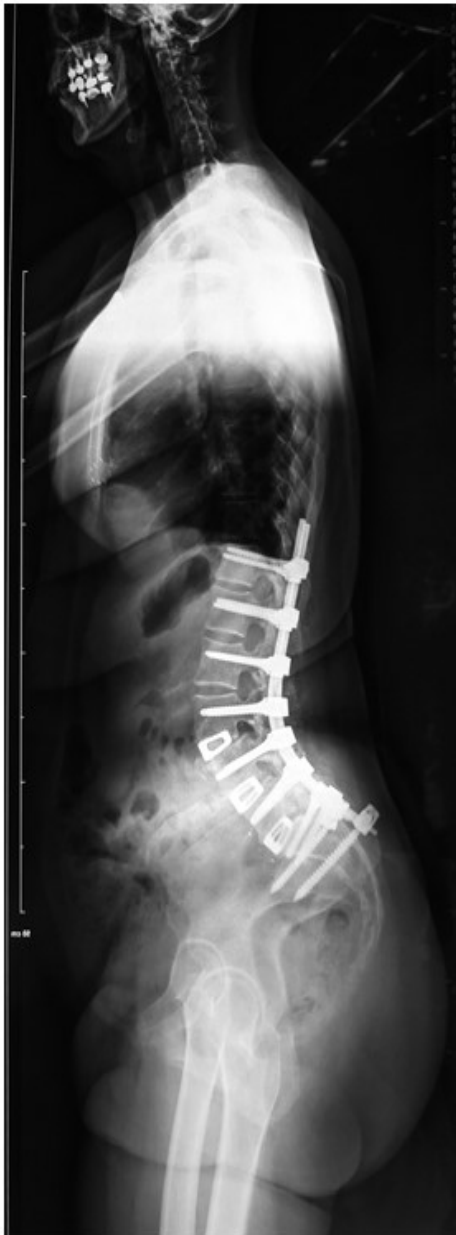Feb 2016



March 2016





July 2016

